

An Atlas of Lumps and Bumps: Part 16

Alexander K. C. Leung, MD^{1,2}—Series Editor • Benjamin Barankin, MD³ • Joseph M. Lam, MD⁴ • Kin Fon Leong, MD⁵

Cystic Hygroma

A cystic hygroma is a benign lymphatic malformation resulting either from an abnormality in the control of lymphatic growth, remnants of embryonic lymphatic tissue that retains the potential for proliferation, or from an arrest in the normal development of the primitive lymphatic channel whereby the peripheral lymphatic vessel becomes sequestered and fails to communicate with the remaining lymphatic system.¹⁻⁵ The formation of a cystic structure containing the accumulated lymphatic fluid outside the lymphatic system is referred to as a cystic hygroma.⁶ Histologically, the lesion consists of multiloculated cysts lined by endothelial cells with serous lymphatic fluid inside the cystic structure. Some cysts communicate with each other, whereas others are separated.

The incidence of cystic hygromas is approximately 1 in 12,000 live births.⁵ The male-to-female ratio is approximately equal.^{3,4} In the majority of cases, the cause is idiopathic.⁷ Cystic hygroma might follow maternal exposure to alcohol, aminopterin, or trimethadione.^{3,4} The condition is more common in patients with chromosomal abnormalities (such as Turner syndrome, Klinefelter syndrome, trisomy 13, trisomy 18, and Down syndrome) and in patients with Noonan syndrome, Proteus syndrome, multiple pterygium syndrome, Roberts syndrome, fetal alcohol syndrome, and Beckwith-Wiedemann syndrome.⁸⁻¹⁰ The condition may also be inherited as an autosomal recessive and autosomal dominant trait.^{7,11}

A cystic hygroma typically presents as a soft, nontender, multilocular cystic swelling that is compressible, fluctuant, and

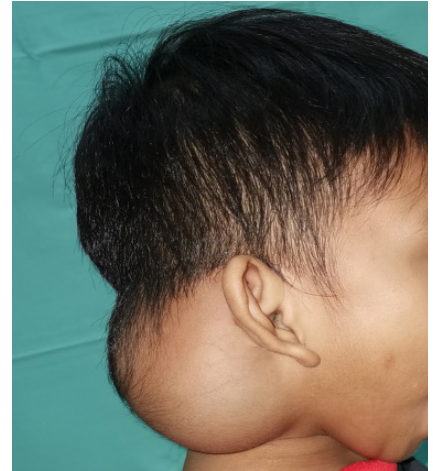

Figure 1. A cystic hygroma typically presents as a soft, nontender, multilocular cystic swelling that is compressible, and fluctuant.

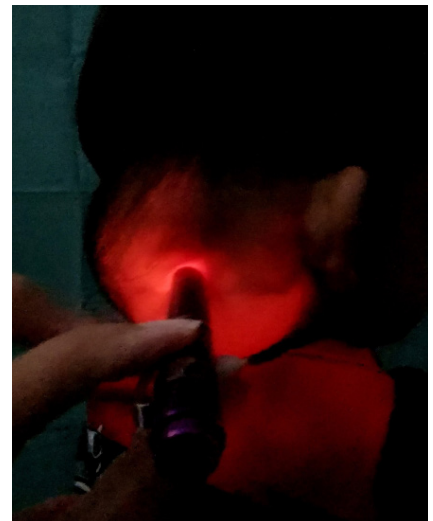


Figure 2. A cystic hygroma typically presents as a brilliantly translucent mass.

brilliantly translucent (**Figures 1 and 2**). The fluid contained inside the cyst is serous, serosanguinous, or straw-colored.^{2,7,9,12} The size varies from 1 to 30 cm

AFFILIATIONS:

¹Department of Pediatrics, University of Calgary, Calgary, Alberta, Canada

²Alberta Children's Hospital, Calgary, Alberta, Canada

³Toronto Dermatology Centre, Toronto, Ontario, Canada

⁴Department of Pediatrics and Department of Dermatology and Skin Sciences, University of British Columbia, Vancouver, British Columbia, Canada

⁵Pediatric Institute, Kuala Lumpur General Hospital, Kuala Lumpur, Malaysia

CITATION:

Leung AKC, Barankin B, Lam JM, Leong KF. An atlas of lumps and bumps, part 16. *Consultant*. 2022;62(5):e25-e26. doi:10.25270/con.2022.05.00001

DISCLOSURES:

Dr Leung is the series editor. He was not involved with the handling of this paper, which was sent out for double-blind, external peer review.

CORRESPONDENCE:

Alexander K. C. Leung, MD, #200, 233 16th Ave NW, Calgary, AB T2M 0H5, Canada (aleung@ucalgary.ca)

EDITOR'S NOTE:

This article is part of a series describing and differentiating dermatologic lumps and bumps. To access previously published articles in the series, visit <https://www.consultant360.com/resource-center/atlas-lumps-and-bumps>.

in diameter.¹⁶ Typically, the lesion is not attached to the skin but may be attached to underlying structures. The overlying skin is normal.⁶ Approximately 50% to 60% of cases are identified before 1 year of age, and 80% to 90% of cases are diagnosed by 3 years of age.^{1,7,13} Onset in adulthood is rare.¹⁴ Approximately 75% of cystic hygromas occur in the neck, typically in the posterior cervical triangle, and lower part of the face.^{1-4,6,7,12,13} Cystic hygromas occur twice as often on the left side of the neck than on the right.⁵ They are usually unilateral but can be bilateral. Approximately 20% of the lesions occur in the axilla.¹⁶ Other less common sites include the mediastinum, omentum, mesentery, retroperitoneum, trunk, inguinal area, extremities, and rarely, in the cheek, suprasternal area, and even in the epidural space and spinal soft tissue.^{1-4,15} The growth of a cystic hygroma is usually, but not always, proportional to the growth of the child. The growth may increase during pregnancy. Cases of rapid enlargement of the lesion over a short period of time have been reported.² The lesion rarely regresses spontaneously.

Although cystic hygromas are benign lesions, they have the potential for extension or infiltration into the surrounding structures such as the soft tissue of the neck and mediastinum and may cross the midline.¹² Depending on the structures involved, airway obstruction, obstructive sleep apnea, dysphonia, dysphagia, feeding problems, and restriction of neck movement might result.^{2,6,7,16} Rarely, huge cystic hygromas may cause neural encroachment.¹ Other potential complications include rupture, infections that may lead to abscess formation, and hemorrhage within the cystic hygroma.^{2,6} Fetal cystic hygroma, especially in the presence of concomitant congenital anomalies and hydrops fetalis, is associated with adverse pregnancy outcomes.¹⁰

Cystic hygromas and their congenital aneuploidies can be first noted during prenatal ultrasonography scanning.¹⁷ Increased nuchal thickness may be noted as early as the first trimester.¹⁷ Postnatally,

the diagnosis is mainly clinical based on the characteristic features of the lesion. Ultrasonography scanning may be used to define the size and extension of the lesion and to demonstrate the multicystic nature of the lesion with no flow on color Doppler study.¹²

REFERENCES

- Guruprasad Y, Chauhan DS. Cervical cystic hygroma. *J Maxillofac Oral Surg.* 2012;11(3):333-336. doi:10.1007/s12663-010-0149-x
- Kamath BS, Chatterjee AS, Chandorkar I, Bhanushali H. Giant recurrent cystic hygroma: a case report. *J West Afr Coll Surg.* 2014;4(2):100-111.
- Leung AKC, Robson WMLM. What's your diagnosis? *Consultant Pediatr.* 2006;5(12):787-789. <https://www.consultant360.com/articles/whats-your-diagnosis>
- Leung AKC. Cystic hygroma. In: Lang F, ed. *The Encyclopedia of Molecular Mechanisms of Disease.* Springer-Verlag; 2009;483-485.
- Ozen IO, Moralioglu S, Karabulut R, et al. Surgical treatment of cervicofacial cystic hygromas in children. *ORL J Otorhinolaryngol Relat Spec.* 2005;67(6):331-334. doi:10.1159/000090043
- Auerbach N, Gupta G, Mahajan K. Cystic Hygroma. In: StatPearls. StatPearls Publishing; February 22, 2022.
- El Sayed M, Touny M, Ibrahim N, Kasb I, Al-Azzawi Z. A rare case of cystic hygroma in neck and extending into thoracic cavity. *Int J Surg Case Rep.* 2020;76:174-177. doi:10.1016/j.ijscr.2020.09.090
- Chen HY, Zheng JQ, Zhang HP. A case report of Turner syndrome associated with fetal nuchal cystic hygroma and bilateral syndactyly of the hands and feet. *Ital J Pediatr.* 2019;45(1):85. doi:10.1186/s13052-019-0680-4
- Gallagher PG, Mahoney MJ, Gosche JR. Cystic hygroma in the fetus and newborn. *Semin Perinatol.* 1999;23(4):341-356. doi:10.1016/s0146-0005(99)80042-1
- Levy AT, Berghella V, Al-Kouatly HB. Outcome of 45,X fetuses with cystic hygroma: A systematic review. *Am J Med Genet A.* 2021;185(1):26-32. doi:10.1002/ajmg.a.61902
- Noia G, Maltese PE, Zampino G, et al. Cystic hygroma: a preliminary genetic study

and a short review from the literature. *Lymphat Res Biol.* 2019;17(1):30-39. doi:10.1089/lrb.2017.0084

- Rahul SK, Kumar B, Bhatnagar A, Sthapak E, Upadhyaya VD. Unusual site for cystic hygroma: a single centre experience. *J Cutan Aesthet Surg.* 2016;9(4):287-289. doi:10.4103/0974-2077.197091
- Avitia S, Osborne RF. Cystic hygroma exacerbated by pregnancy. *Ear Nose Throat J.* 2005;84(2):78-79.
- Elshaar K, AbuAleid L. Adult-onset giant cervical cystic hygroma with pressure manifestations on aerodigestive tract, managed surgically: reporting of a rare case. *Ann R Coll Surg Engl.* 2019;101(3):e84-e87. doi:10.1308/rcsann.2018.0214
- Payne C, Gigliotti MJ, Castellvi A, Yu A. Rare case of cystic hygroma in the epidural space resulting in multilevel spinal cord compression. *BMJ Case Rep.* 2019;12(8):e230326. doi:10.1136/bcr-2019-230326
- Wygant CM, Cohle SD. Fatal airway obstruction in a man with a cystic hygroma. *Am J Forensic Med Pathol.* 2018;39(3):250-252. doi:10.1097/PAF.0000000000000404
- Behera S, Bawa M, Kanojia RP, Saha PK, Singh T, Samujh R. Outcome of antenatally diagnosed cystic hygroma - Lessons learnt. *Int J Pediatr Otorhinolaryngol.* 2020;138:110227. doi:10.1016/j.ijporl.2020.110227